

Case Reports

Yam B Roka, MS, MCh

Department of Neurosurgery
Neuro Cardio and MultiSpeciality hospital
Biratnagar, Nepal

Narayani R Bhattarai, MBBS, MS

Department of Ophthalmology
Neuro Cardio and MultiSpeciality hospital
Biratnagar, Nepal

Address for Correspondence:

Yam B Roka, MS, MCh
Department of Neurosurgery
Neuro Cardio and MultiSpeciality hospital
Biratnagar, Nepal
Email: dryamroka@yahoo.com

Received, 17 March 2017

Accepted, 27 March, 2017

Giant Sellar/Supra Sellar Arachnoid Cyst with Visual Loss: 5 Years Follow-Up Post Cystocisternostomy

Sellar/suprasellar arachnoid cyst can present with headache, endocrine dysfunction, psychomotor abnormalities, chronic hydrocephalus, vertigo, optic nerve and visual deficits and asymptotically. We report a case managed with cystocisternostomy and long term follow-up with good improvement of his visual function.

Key Words: arachnoid cyst, craniopharyngioma, cystoventriculostomy, cystoperitoneal shunting sella/supra sella

Arachnoid cysts are developmental anomalies involving duplication or splitting of the arachnoid membrane mostly diagnosed incidentally and was first described in 1831 by the English physician Richard Bright in 1789-1858.¹¹ The large majority are often found in the middle cranial fossa with sellar/suprasellar arachnoid cyst (SSAC) comprising of 9-15%.^{4,9} SSAC can present with headache, endocrine dysfunction, psychomotor abnormalities, chronic hydrocephalus, vertigo, optic nerve and visual deficits and asymptotically.

Case Report

A 35-year-old male was brought by his relatives with history of headache and progressive loss of vision for 6 months. For the last few weeks he had loss of complete vision on left side and was completely dependent for mobilization and activities of daily life-independent (ADL). Preoperative blood and endocrinology (Thyroid function [TSH 3.0mIU/ml], Prolactin [9.27 ng/ml] and Growth hormone [0.270ng/ml]) work-up was normal. Ophthalmological examination showed visual acuity in right eye as perception of light (PL) and projection of rays (PR) accurate. The visual acuity on the left eye was no perception of light (NPL). The fundus examination showed early papilloedema in right eye and severe papilloedema in left eye. Humphrey Visual field (HVF) could not be done.

Pterional approach and cyst marsupialisation with cystocisternostomy was done. It contained clear fluid under pressure and had displaced both the optic nerve and chiasma with the left optic nerve being completely thinned and pale looking. The optic nerves were freed from the cyst and the contents cleared. The pituitary stalk was normal. Histopathological report showed numerous cystic spaces lined by pseudo stratified epithelium at places by tall columnar and flatted epithelial cells suggestive of arachnoid tissue. He was discharged on the 7th day and repeat CT at 2 weeks showed 20% residual cyst. He was relieved of headache on the first post-operative day and was followed up regularly. At 5 years there is progressive improvement of vision to present 20/20 (6/6) in right eye and 6/18 (20/60) in left eye. There is no further improvement of vision even with glasses in the left eye. The fundus examination on the right eye is normal and there is temporal pallor of the optic disc on the left eye. The HVF examination showed right temporal hemianopia and gross reduction of the field in left eye. The latest CT after 5 years showed no residual SSAC (**Figure 1**). He can presently ambulate freely and is ADL independent.

Discussion

The incidence of arachnoid cyst range between 0.2 and 2.6 % with the majority being found incidentally in CT or MRI. They are commoner in males. Of the

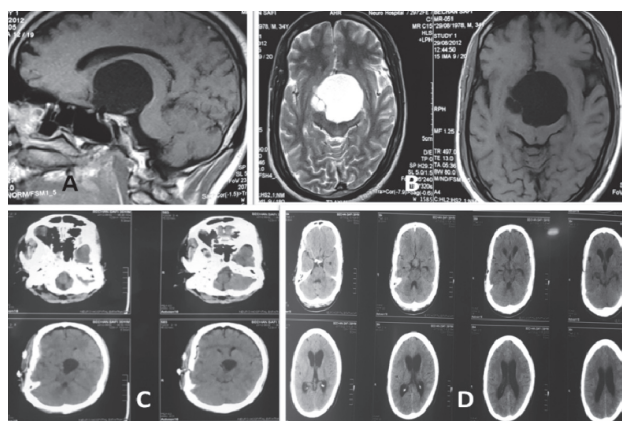


Figure 1. MRI T1 and T2 image in axial and sagittal views taken in 2012 showing the SSAC (A,B), postoperative scan showing 20% residual cyst (C) and latest scan in March 2017 showing complete absence of the SSAC (D)

SSAC, the suprasellar types are more common with the mechanism of formation as for arachnoid cyst in other regions. The differential diagnosis of SSAC includes cystic craniopharyngiomas, pituitary cystic adenomas, Rathke's cleft cysts, epidermoid tumours, empty sella, inflammatory cysts, and ependymal cysts.^{7,8,12} SSAC can coexist with pituitary adenoma. In addition to the symptoms mentioned above precocious puberty can be presenting sign in 10-40% secondary to damage to the ventromedial nucleus of the .^{1,3,13} Diagnosis is with help of CT or MRI showing non-enhancing hypo-dense lesions and hypo-intense on T1 and Hyper-intense on T2 with characteristics as of CSF respectively. If symptomatic, surgery is the treatment of choice and options include cyst aspiration, wall fenestration, wall excision, cystoventriculostomy, cystosubdural shunt, cystoperitoneal shunting and endoscopic transcranial or trans nasal excision.^{8,12} Recurrent cases may need placement of a subcutaneous reservoir or change of procedure.^{2,5,6} This case has demonstrated that symptomatic arachnoid cyst if treated early by surgical intervention can alleviate the symptoms and even improve visual outcome in those compromised. Visual and endocrinological symptom improvement have been documented by other authors after surgery.¹⁰

Conclusion

SSAC are rare lesions that are mostly asymptomatic but can present with a variety of clinical signs and symptoms. Early surgical treatment for symptomatic lesions can result in good clinical outcome.

References

- Adan L, Bussieres L, Dinand V, Zerah M, PierreKahn A, Brauner R. Growth, puberty and hypothalamic-pituitary function in children with suprasellar arachnoid cyst. **Eur J Pediatr** **159** : 348–355, 2000
- Baykan N, Isbir O, Gercek A, Dagnar A, Ozek MM. Ten years of experience with pediatric neuroendoscopic third ventriculostomy: features and perioperative complications of 210 cases. **J Neurosurg Anesthesiol** **17**: 33-37, 2005
- Brauner R, Pierre-Kahn A, Nemedi-Sandor E, Rappaport R, Hirsch JF. Precocious puberty caused by a suprasellar arachnoid cyst. Analysis of 6 cases. **Arch Fr Pediatr** **44**: 489-493 ,1987
- Bright R. Serous cysts in the arachnoid, in Rees, Orme, Brown, Green (eds). **Diseases of the Brain and Nervous System. Part I. London: Longman Group Ltd**, 1831
- Buxton N, Vloeberghs M, Punt J. Flexible neuroendoscopic treatment of suprasellar arachnoid cysts. **Br J Neurosurg** **13**: 316-318, 1999
- Caemaert J, Abdullah J, Calliauw L, Carton D, Dhooge C, van Coster R. Endoscopic treatment of suprasellar arachnoid cysts. **Acta Neurochir (Wien)** **119**: 68-73, 1992
- Dubuisson AS1, Stevenaert A, Martin DH, Flandroy PP. Intracellular arachnoid cysts. **Neurosurgery** **61** : 505-513, 2007
- Güdük M, HamitAytar M, Sav A, Berkman Z. Intracellular arachnoid cyst. A case report and review of the literature. **Int J Surg Case Rep.****23**: 105-108, 2016
- Güzel A1, Trippel M, Ostertage CB. Suprasellar arachnoid cyst: a 20- year follow-up after stereotactic internal drainage: case report and review of the literature. **Turk Neurosurg** **17** : 211-218, 2007
- Meyer FB, Carpenter SM, Laws ER Jr. Intracellular arachnoid cysts. **Surg Neurol** **28**:105-110 1987
- Rengachary SS, Watanabe I. Ultrastructure and pathogenesis of intracranial arachnoid cysts. **J Neuropathol Exp Neurol** **40**: 61-83, 1981
- Rizk E, Chern JJ, Tagayun C, Tubbs RS, et al. Institutional experience of endoscopic suprasellar arachnoid cyst fenestration. **Childs Nerv Syst.** **29** : 1345-1347, 2013
- Sweasey TA, Venes JL, Hood TW, Randall JB. Stereotactic decompression of a prepontine arachnoid cyst with resolution of precocious puberty. **Pediatr Neurosci** **15**: 44–47, 1989