Original Article

Nepal Journal of Neuroscience 10:61-67, 2013

Management of Pyogenic Brain Abscess in Children: Review of 50 Cases

Mohan R Sharma, MS
Division of Neurosurgery
Department of Surgery
Tribhuvan University Teaching Hospital
Maharajgunj, Kathmandu, Nepal

Address for Correspondence:
Mohan Raj Sharma, MS
Associate Professor of Surgery (Neurosurgery)
Department of Surgery
Tribhuvan University Teaching Hospital
Kathmandu, Nepal
Email: mohanrajsharma@gmail.com

Received, 1 November, 2013
Accepted, 12 November, 2013

The objective of this study was to review the clinical, radiological, bacteriological and operative characteristics of 50 children with brain abscess treated surgically, and to correlate these data with the final outcome at discharge in order to identify possible prognostic criteria.

A total of 70 patients were found to have infections needing surgical interventions in children under 17 years of age over 8-year period. Out of those, 50 had pyogenic brain abscess requiring surgery. Thirty of the patients were male and 20 were female. Commonest age group affected was 10-15 years of age (21 out of 50). The most common condition preceding the abscess formation was ear infection (30 out of 50). The most common clinical features in the order of frequency were headache, fever, vomiting, altered sensorium and a focal neurological deficit. Abscesses were more common on the left side (33 vs. 17). Multiple abscesses were found in 9 patients whereas solitary was detected in 41 cases. Accurate preoperative diagnosis based on CT and/ or MRI was possible in 49 cases. Treatment included burrhole aspiration in 46 patients as initial mode of treatment. Ten of these patients required reaspiration. Two patients subsequently required craniotomy and excision of abscess as they failed to respond to repeated aspiration. Four patients underwent craniotomy and drainage of pus or excision of abscess as the initial mode of treatment. Culture of pus was positive in only 17 patients and Proteus spp. was the commonest organism isolated (7 out of 17). Thirty-day hospital mortality was 8.0 %.

There is a high predilection for brain abscess in children with ear infections who are between 10-15 years of age. With the good operative intervention and good perioperative antibiotics, mortality has been reduced to 8.0 %.

Key Words: brain abscess, burrhole, craniotomy, outcome

Brain abscess is a life-threatening and unfortunately still a common disease in the developing world like Nepal. Lack of adequate control of ear infection and meningitis secondary to poor living conditions prevalent in this part of the world has been cited to be the predisposing factors for the development of brain abscess in children.[10,11,12,21] Timely diagnosis and institution of medical and surgical therapy makes a significant difference in the final outcome. In this study, clinical, radiological bacteriological and operative characteristics of all patients under 15 years of age admitted to Tribhuvan University Teaching Hospital, Kathmandu, Nepal with documented brain abscess over 8-year period were analyzed.

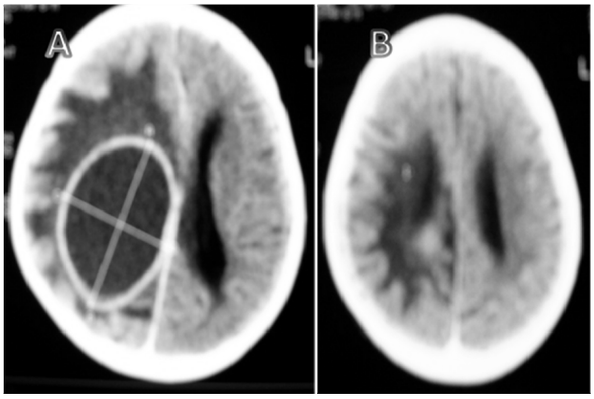

Figure 1: CT scan of head of an 8-year old child presenting with fever and altered sensorium at the time of admission. Post contrast (A) scans showing an area of low density with a marked ring around the low density area. Contrast CT scan of head (B) of the same patient after burrhole aspiration and completion of antibiotics treatment, 6 weeks after admission. Note the complete disappearance of the abscess. Gliosis in the area is evident.

Materials and Methods

Ninety patients with symptoms of suppurative intracranial infections (brain abscess, subdural and extradural empyemas) diagnosed by CT (computerized tomography) scan and/or MRI (magnetic resonance imaging) scan of the head were operated at Tribhuvan University Teaching Hospital, Nepal from February 1995 to July 2003. Seventy patients were below 15 years of age. Fifty-five of these patients were found to have brain abscess. Five patients had tubercular and amoebic brain abscesses and were excluded from the study. Thus 50 children with documented pyogenic abscess constitute the basis of this study. Clinical, radiological, bacteriological and operative data which were acquired prospectively and kept in the computerized data bank of the division of Neurosurgery at TU Teaching Hospital were reviewed. Additional information in some patients was obtained from the hospital charts. We described the following parameters in this patient population: age, sex, history of ear infection and meningitis, Glasgow coma scale (GCS) on admission, presence or absence of hydrocephalus at admission, admission CT findings, Operative findings, number and type of operative procedure needed, length of hospital stay, and Glasgow outcome scale (GOS) at discharge from hospital.[8]

Management Protocol

Each patient with suspected brain abscess was evaluated by the neurosurgical team. Clinical examination of the patient was performed noting the level of consciousness and presence or absence of focal deficit (s) in particular. A plain and post contrast CT scan was obtained routinely in all patients and size, location and number of lesions were noted in detail. After admission, a decision was made by the neurosurgeon depending on the patient's neurological condition and imaging findings to operate. Patients with brain abscess were routinely offered burrhole and aspiration of pus as the first line of treatment in addition to put them on anticonvulsants. Patients with severe coagulopathy or those declining surgery were not operated and were excluded from the study. Amount and nature of pus was noted intraoperatively. All patients were operated under general anesthesia. Patients were routinely put on triple antibiotics and switched to a different one only when culture report indicated different antibiotics. A total of 6 weeks of intravenous antibiotics was instituted. A CT scan was obtained on the average in a week of surgery and at the completion of antibiotics treatment or when patient developed a decline in the GCS by two points or new fever.

The short-term neurological outcome was assessed using GOS at the time of hospital discharge or death.

Statistical Analysis

Statistical analysis of the various pre- and postoperative clinical data was performed using standard software. P values of less than 0.05 were considered significant. We considered the effects of age, sex, ear infection, meningitis, GCS score at the time of admission, presence of hydrocephalus, number and location of abscesses on outcome, and the length of hospital stay and short-term outcome.

Results

Seventy patients were found to have brain abscess over 8-year period. Of these fifty patients under 17 years of age with documented pyogenic brain abscess were identified.

Demographics and Risk Factors

Table 1 summarizes the demographic characteristics and risk factors for the development of brain abscess of the 50 patients. The average age of the patients was 8.8 years ranging from 3 months to 14 years and comparison with respect to patient age showed a higher incidence of brain abscess in the 10-14 year group. There were 4 (8.0 %) infants aged up to 1 year. There was slight male predilection (M: F 29:21). Regarding risk factors, a history of recent or past ear infection was found in 30 patients whereas in 9 patients no identifiable predisposing factor was found. Brain abscess following recent pyogenic meningitis was noted in 4 patients whereas neglected compound fracture of skull was noted in 2 patients. Mean length of hospital stay was 30.5 days.

Clinical Features

Various clinical features of the 50 patients are given in **Table 1.** Headache was the commonest presenting symptom followed by fever and vomiting. Seizures were noted only in 6 patients. More than one symptom was present in 40 patients.

Imaging Characteristics

Forty-six patients had CT scan of the head whereas 4 had MRI scan of the head. CT scan was accurate in identifying brain abscess in all cases whereas in one patient the preoperative diagnosis based on MRI was high-grade glioma. Multiple abscesses were noted in 9 patients. Anatomically, cerebral hemisphere was the commonest location followed by cerebellum (35 vs. 14). There was a strong left-sided predominance of brain abscess (33 patients with left-sided abscesses versus 16 patients with right-sided abscesses). One patient had brainstem abscess.

Associated Conditions

Four patients had hydrocephalus at presentation requiring ventriculostomy; 2 of these patients eventually required permanent V-P shunt placement once the initial infection was eradicated. Two patients had associated subdural empyema and one patient had associated osteomyelitis of overlying skull.

Operation

Table 2 summarizes the various surgical procedures performed in 50 patients. Treatment in our series included burrhole-aspiration in 46 patients as initial mode of treatment. Four patients underwent craniotomy and evacuation of pus or excision of abscess as the initial mode of treatment. Four patients required craniotomy and evacuation of pus as initial procedure. One patient had brain stem abscess; two patients had associated subdural empyema; and in one patient the preoperative diagnosis was high grade glioma. Ten patients with brain abscess who initially had burrhole tapping required reaspiration sometime between 1 week to 3 weeks while one patient required aspiration for 3 times. Two patients subsequently required craniotomy and excision of abscess as they failed to respond to initial aspiration. Both patients had multiple abscesses and had impending herniation. The average number of total neurosurgical procedures was 1.3/patient. All but one patient who survived showed resolution of abscess at the end of 6 weeks. One patient continued to show a ring-enhancing lesion even 3 months after the treatment though the patient was truly asymptomatic.

Parameters	No. of patients (%out of 50)
Age years (mean)	8.8±
Sex Ratio (M:F)*	29:21
Predisposing factors	
Otogenic	30
Meningitis	4
Paranasal sinusitis	2
Neglected cranial wound	2
Systemic sepsis	2
CHD$^{\psi}$	1
Idiopathic	9
Clinical Features	
Headache	32
Fever	28
Vomiting	12
Altered sensorium	10
Focal deficit	10
Seizure	6

Table 1: Demographics, predisposing factors and clinical features in 50 children with pyogenic brain abscess[a]

**M, male; F, female, $^{\psi}$CHD = Congenital heart disease*

Procedure	No. of patients
Burrhole -aspiration	46
Craniotomy	4
Burrhole- aspiration subsequently requiring craniotomy	2

Table 2: Operative procedures performed in 50 children with pyogenic brain abscess

Bacteriological Spectrum

Table 3 summarizes the microbiological spectrum of 50 children with brain abscess. Culture of pus was positive in only 17 patients and Proteus mirabilus was the commonest organism isolated (7 out of 17). The next most common organism was Kleibsiella pneumonia which was cultured

Organism	No. Of patients
Proteus mirabilus	7
Klebsiella pneumonia	4
Staphylococcus aureus	2
Multiple organisms	4
Sterile culture	33

Table 3: Bacteriological spectrum for 50 patients with pyogenic brain abscess

Grading	No. of patients
Good	42
Disabled but independent	2
Disabled and dependent	2
Persistent vegetative state	0
Death	4

Table 4: Glasgow outcome scale at discharge for 50 children with pyogenic brain abscess

in 4 cases whereas mixed growth was isolated in 4 cases. Cultures from 33 patients were sterile.

Outcome and Length of Stay

As shown in Table 4, using the Glasgow Outcome Scale (GOS) to grade the recovery at discharge, 44 (%) patients had favorable outcome (good and minor disability). Two patients experienced poor outcomes (disabled and dependent) as they had major neurological deficit at discharge. Four patients (8.0%) died (Figure 1- Bar chart). All patients who died either came to the hospital in a neurologically poor condition or suffered a significant preexisting medical condition such as chest infection or cyanotic heart disease. Some of these patients suffered a nosocomial pneumonia ultimately leading to death.

Mean length of hospital stay for all patients in this series was 30.9 days with as short as 6 days to a maximum of 66 days.

Discussion

Despite advances in the diagnosis with the advent of CT scanning, improved isolation techniques for microorganisms and development of good antibiotics, brain abscess is still one of the common and often formidable intracranial suppurations in the developing world where there is high prevalence of ear infection and meningitis.

Our report constitutes a relative large clinical series in children with brain abscess in the modern era and represents our 8-year experience of management of this condition. Brain abscess was the most common form of intracranial suppuration in our series as 50 out of 70 (71.4%) children with intracranial suppuration had brain abscess.

Demographics and Risk Factors

The demographic characteristics of this study population were very similar to those observed in other series of pediatric patients with pyogenic brain abscess.[4,13,16,17] Most of the patient fell in the 10-14 year age group which is consistent with previously published results.[13,14] In the report by Wong et al., in a review of 83 children with brain abscess, the average age was 7 years with 12% less than 1 year old.23 In the report by Cuirea et al., in a review of 59 children the average age was 7.1 years with the most affected age group being 7-11 years.[3] This is consistent with the finding that children of this age group are prone to upper airway and ear infection which was found significantly in our series. In our series there was slight male predilection though not to the point of reaching statistical significance which is in accordance with the previously published reports.[3,23] The source of infection is frequently obvious. Brain abscess is caused either by direct extension of an adjacent infection ,for example, meningitis or mastoid infection [3,11,21,25] paranasal sinus infection,[18,25] or dental infection,[14] or by hematogenous seeding of the brain parenchyma from a distant source.[3] With the exception of dental source, all of these causes are represented in our series. Otogenic source (60.0%) was the commonest predisposing factor in our series which is explained by a high incidence of untreated ear infection in our part of the world. This cooroborates with the previous reports.[13,21] In contrast in the cooperative study of 83 children with brain abscess, by Wong and his collegues, only 6 % had otogenic souce of infection.[23] In our series the next most common predisposing factor was meningitis which was found in 8.0% of cases. Three out of four cases were post-meningitic. This is consistent with the previous reports that infants are more prone to get post- meningitic brain abscess.[3]

Cerebral abscess related to cyanotic congenital heart disease is one of the major causes of morbidity and mortality in children.[9] Though in other series with brain abscess in children it has been noted to be a significant factor, [21,23] we had only one patient in our series. This is probably due to low index of suspicion and subtle

neurological features may have been ascribed to be due to cardiac condition in our part of the world.

Brain abscess due to inadequate and inappropriate management of compound fracture of skull is represented fortunately in only two patients (4.0 %) in our series. The dead and devitalized bony fragments and other soft tissues provide a nidus for infection which later evolves into an abscess. The reported figure for this risk factor varies from 4.8 % to 17.0 % .[5,23]

Systemic sepsis as a risk factor was represented in two patients in our series. Both of them had pneumonia. The reported incidence of this type of brain abscess in children from the cooperative study by Wong et al was 8.4%.[23]

In a large proportion of cases the predisposing factor is undermined and the number of patients of this type vary from as low as 5.0 % [5] to 40.0 %.[21] In our series, nine patients (18.0%) had no identifying cause found.

Contrary to previously published reports dental infection was encountered in none of our patients.[14] This could well be due to the bias due to small sample size of the study population.

Clinical Features

The most common presenting clinical features of brain abscess are fever, headache, vomiting, altered sensorism and focal neurological deficit depending upon the size, multiplicity and location of the lesions and presence or abscess of systemic sepsis(Garvey G). Although no symptoms and signs are pathognomonic for brain abscess, the presence of afore-mentioned features in the setting of suppurative ear infection, systemic or lung infection and congentical cyanotic heart disease should strongly suggest the diagnosis of an brain abscess. The relative frequency of these symptoms varies between different reports.[3,13,21,23] In our series, headache was the most common symptom (64.0%) followed by fever (56.0%), vomiting (24.0%), altered sensorium (20.0%) and focal neurological deficit (20.0%). In the report by Theophilo et al, paresis and cranial nerve palsies were the most common presenting features.[22]

The level of consciousness at admission has been found to be the most important predictor of final outcome by several investigators.[3,15,21] In our series 10 patients had altered sensorim (both had Glasgow coma scale of less than 8) as one of the presenting symptoms and two of these patients died.

Imaging Characteristics

In the modern era the diagnosis of abscess and monitoring of its evolution is done by CT or MRI scanning and details of CT findings during different stages have been described elsewhere.[2] In our series CT scan of the head was the predominant imaging modality for the diagnosis of the condition and this was used exclusively for the monitoring of abscess resolution. In our series CT scan was 100% sensitive and specific where as in one case MRI failed to diagnose the abscess preoperatively. In the report by Wong et al, 90.4% out of 83 cases were detected by CT scan of head.[23]

Multiple abscesses were found in nine (18.0%) cases in our series. In the major pediatric series this has varied from as low as 13.0 % to 42.0%.[13,21] In the report by Mallik et al out of 47 patients, 20 (42.0%) had multiple abscess.[13] The very low incidence of multiple brain abscesses in our series is probably due to the fact that hematological spread due to systemic sepsis was not an important predisposing factor. Uusally brain abscess due to hematogenous cause tend to be multiple.[3]

Brain abscesses were preferentially located more frequently on the left side (66.0%) in our series.

The location of the abscess inside the brain is largely dominated by the location of the primary infective focus unless it is a systemic sepsis. Anatomically cerebral hemispheric lesions dominated our series (70.0%) consistent with previous reports.[3,5,23] In 14 (28.0 %) cases, the lesions were found in the cerebellum and one patient had brain stem abscess. Interestingly, in a large series by Cuirea at al, none of the patients had cerebellar abscess.[3]

Associated Conditions

Hydrocephalus was detected in 4 (8.0%) patients upon admission requiring intervention in our series. Similarly 2 patients had associated subdural empyema on the same side and one patient had osteomyelitis of the overlying bone. Two of the four patients required permanent V-P shunt placement. Cuirea et al. in their series of 59 patients noted hydrocephalus requiring insertion of ventriculoperitoneal shunt in 5 patients.[3]

Treatment

The most commonly agreed upon treatment for brain abscess is the combination of surgical aspiration with or without excision of the abscess in addition to antimicrobial therapy.[18,19,24] In addition treatment should also be directed towards the treatment of the source of infection, if any. Although antibiotics continue to be an important part of treatment of brain abscess in children, there is much controversy about the nature of surgical intervention-aspiration versus excision. It is important that the antibiotic therapy chosen should be targeted against the specific organism based on the likely source of infection

and later on sensitivity on culture of the specimen. The appropriate duration of antibiotics treatment is still open to debate but a 6-8 weeks of treatment is generally advised in the aspiration group and a shorter duration for the excision group. We personally preferred to do burrhole and aspiration of abscess as the initial line of treatment due to the ease of doing through a burrhole, minimal cerebral trauma and small magnitute of surgery in already sick children. Cranitotomy and excision was limited to cases associated with other intracranial conditions (subdural empyema and osteomyelitis) or when the diagnosis was in confusion. Primary excision of abscess has its proponets, [1,14,20,22] but has several disadvantageous-big surgery, long anesthesis, not being feasible in eloquent and deep seated areas of brain . Children in severe condition may not torelate long anesthesia. And usually multiple abscesses are not amenable to good surgical excision.[3] Excision is generally preferred in posttraumatic abscesses where a nidus (such as a bone fragment or a foreign body) is considered to be responsible for producing the lesion. Though in a series of posterior fossa abscesses where excision of the abscesses was performed in all cases, the overall mortality was found to be 0, the number of cases were too small to draw any conclusions.[1] In the report by Tekkok et al, more than half of the patients were treated by primary excision.[21] In the report by Moss et al, the predominant mode of treatment was by excision of the abscess.[14]

Bacteriological Spectrum

The microbiological profile of pus from brain abscess in children varies in different series.[3,14,16] In our series culture was positive only in 34 % of our cases. This low identification may in part be due to our inability to isolate the fastidious organism especially anaerobic species in our set up. In the report by Tekkok et al, microorganisms were identified in 54% of patients.[21] Staphylococci, streptococci and Proteus were the dominating microorganisms. In the report by Moss et al, 26% of culture of the specimens were negative for organisms and streptocooci were the most common organism isolated. [14] In the report by Theophilo, 6 out of 19 cases were sterile.[22] In the report by Mallik et al, cultures were postive in 54.8 % of cases and staphylococci, Proteus, and Pseudomonas were the frequently isolated organisms from the culture.[13] In the report by Wong et al, organisms were isolated in 49.2 % of cases and streptococci were the most common organism isolated.[23] In the report by Ershin et al, Streptococci, staphylococci and Ptroteus were the most frequently recoverd organisms.[5] In the report by Ciurea et al, Gram +ve cocci were the commonest organism isolated, sterile cultures in 19 cases (32.2%).[3]

Outcome and Length of Stay

In the report by Tekkok et al, overall mortality was 15.5%.[21] In the report by Malik et all, the overall mortality was 44.7 %.[13] In the report by Wong et al, there was 19.3 % mortality.[23] The overall mortality in the series by Ershin was 20.0%.[5] In the report by Cuirea et al, the overall mortality was 11.86 %.[3] Mean duration of stay in their series was 68.2 days.

n this series, the overall short-term outcome of children with pyogenic abscess was favorable; 88.0% had good or minor disability at the time of discharge. These data are consistent with the reported literature.[3,13,21,23]

The 8.0% mortality rate in our series warrants clarification. All but one patient had significant comorbid medical conditions and referral to us in a very late stage. Though we cannot deny the fact that the surgical intervention could well have exacerbated the preexisting conditions, it is hard to justify all deaths due to intracranial insultsurgery *per se*. Another confounding factor has been the inability to get the right type of antibiotics.

Our series includes several unusual features: a) Most of the series published have included some patients where no surgery was performed hence the diagnosis can not be taken as confirmed in all patients. Our series includes only those patients where the diagnosis was confirmed at surgery, b) our series includes children with pyogenic abscesses only, excluding tubercular and amoebic abscesses. Most other series have tubercular varieties as well. As natural course of disease as well as treatment differ considerably between these groups lumping together may not be as well representative as in our report.

Finally, the limitations of our study also deserve mention. This study is retrospective in nature, although data was acquired prospectively, and inherent biases associated with this cannot be ignored. This is also a single institutional study and therefore may not be generalized for other regions. Moreover, potential introduction of errors due to small sample size cannot be ruled out.

Conclusions

The demographic, clinical, radiological and operative characteristics of pediatric patients with pyogenic brain abscess confirmed at surgery have been described in a consecutive series of 50 patients. In addition, we correlated the above characteristics with the final outcome in these group of patients. The results demonstrated several important clinical facts, as follows: 1) Suppurative intracranial infections are still an important cause of morbidity and mortality in our set up. 2) Timely institution of therapy- surgical and medical improves the overall

prognosis. 3) The presence of hydrocephalus at admission correlates significantly with the subsequent development of poor outcome.

References

1. Agrawal D, Suri A, Mahapatra AK: Primary excision of pediatric posterior fossa abscesses—towards zero mortality? A series of nine cases and review. **Pediatr Neurosurg 38:**63-7, 2003
2. Britt RH, Enzmann DR: Clinical stages of human brain abscesses on serial CT scans after contrast infusion. Computerized tomographic, neuroplathological, and clinical correlations. **J Neurosurg 59:**972-989, 1983
3. Ciurea AV, Stoica F, vasilescu G, Nuteanu L: Neurosurgical management of brain abscesses in children. **Childs Nerv Syst 15:**309-17, 1999
4. Donaldson G, Webster D, Crandon IW: Brain abscess at the University Hospital of the West Indies. **West Indian J 49:**212-5, 2000
5. Ersahin Y, Mutluer S, Guzelbag E: Brain abscess in infants and children. **Childs Nerve Syst. 10:**185-9, 1994
6. Fuentes S, Bouillot P, Regis J, et al: Management of brain stem abscess. **Br J Neurosurg 15:**57-62, 2001
7. Garvey G: Current concepts of bacterial infections of the central nervous system. Bacterial meningitis and bacterial brain abscess. **J Neurosurg 59:**735-744, 1983
8. Jennett B, Bond M: Assessment of outcome after severe brain damage. A practical scale. **Lancet 1:**480-484, 1975
9. Kagawa M, Takeshita M, Yato S, et al: Brain abscess in congenital cyanotic heart disease. **J Neurosurg 58:**913-917, 1983
10. Kumar R, Pandey CK, bose N, Sahay S: Tuberculous brain abscess: clinical presentation, pathophysiology and treatment in children. **Childs Nerv Syst 18:**118-23, 2002
11. Long YT, Mahmud R, Sani A, Saim L: Complications of otitis media requiring surgical intervention. **Asian J Surg :**170-4, 2002
12. Lu CH, Chang WN, Lin YC, et al: Bacterial brain abscess: microbiological features, epidemiological trends and therapeutic outcomes. **QJM 95:**501-9, 2002
13. Malik S, Joshi SM, Kandoth PW, et al: Experience with brain abscesses. **Indian Pediatr. 31:**661-6, 1994
14. Moss SD, McLone DG, Arditi M, Yogev R: Pediatric cerebral abscess. **Pediatr Neurosci 14:**291-296, 1988
15. Qureshi HU, Habib AA, Siddiqui AA, et al: Predictors of mortality in brain abscess. **J Pak Med Assoc 52:**111-6, 2002
16. Renier D, Flandin C, Hirsch E, et al: Brain abscesses in neonates. A study of 30 cases. **J Neurosurg 69:**877-882, 1988
17. Saez-Llorens X: Brain abscess in children. **Pediatr Infect Dis 14:**108-14, 2003
18. Sharma BS, Gupta SK, Khosla VK: Current concepts in the management of pyogenic brain abscess. **Neurol India. 48:**105-11, 2000
19. Skoutelis AT, Gogos CA, Maraziotis TE, Bassaris HP. Management of brain abscesses with sequential intravenous/oral antibiotic therapy. **Eur J Clin Microbiol Infec Dis. 19:**332-5, 2000
20. Takeshita M, Kagawa M, Izawa M, Takakura K: Current treatment strategies and factors influencing outcome in patients with bacterial brain abscess. **Acta Neurochir (Wien)140:**1263-70, 1998
21. Tekkok IH, Erbengi A: Management of brain abscess in children: review of 130 cases over a period of 21 years. **Childs Nerve Syst. 8:**411-6, 1992
22. Theophilo F, Markakis E, Theophilo L, et al: Brain abscess in childhood. **Childs Nerve Syst. 1:**324-8, 1985
23. Wong TT, Lee LS, Wang HS, et al: Brain abscesses in children- a cooperative study of 83 cases. **Childs Nerve Syst. 5:**19-24, 1989
24. Yamamoto M, Fukushima T, Hirakawa K, et al: Treatment of bacterial brain abscess by repeated aspiration—follow up by serial computed tomography. **Neurol Med Chir (Tokyo) 40:**98-104, 2000
25. Younis RT, Lazar RH, Anand VK: Intracranial complications of sinusitis: a 15-year review of 39 cases. **Ear Nose Throat J 81:**636-8, 640-2, 644, 2002